

Unilateral Dermoid Ovarian Cyst In Nulliparous Women

Mona Mohammed Al gobbi
Mona. Algobbi@su.edu.ly

Obstetrics and Gynecology Department, Faculty of Medicine, Sirte University, Libya

Abstract

Ovarian dermoid cyst are the most common germs cell tumors of ovarian and make up about two thirds of all ovarian tumors. They occur mostly in women between the second and fourth decades of the life and usually present with non-specific symptoms including lateral onset menarche and menstrual cycle abnormalities.

It is reported the case of 23 years old women, who presented with sudden onset of severe lower abdominal pain and nausea, similar episode of pain were experienced in the previous few months and diagnosed as a case of unilateral ovarian cyst. She was found to have unilateral – ovarian torsion caused by adnexal mass. She was managed by detorsion and Rt. Cystectomy and Laparotomy at Ibn- Sina Teaching Hospital.

Mature teratoma is an important gynecological morbidity whose prompt diagnosis and management can ever serious complication. We therefore preset this case to raise physician awareness on common presentation of common gynecological tumor.

Keywords: Unilateral dermoid cysts, cystic teratoma, detorsion cystectomy and laparotomy

1. Background

Ovarian dermoid cyst or mature teratoma are germ cell tumor composed of well differentiated derivatives of 3 germ layer's ectoderm, mesoderm, and endoderm [1]. There are the most common germ cell tumour of the ovaries and make up to 20 to 30% of all ovarian tumors [2]. Of all patients undergoing emergency surgery for acute pelvic pain, approximately 2.7% of cases are caused by ovarian torsion [3]. It is defined as the partial or complete rotation of adnexa around its vascular

axis that may cause and interruption in the ovarian blood and lymphatic flow [4]. It is reported to occur at any age from pre-puberty to post menopause with the greatest incidence in women 20 – 30 years of age [5].

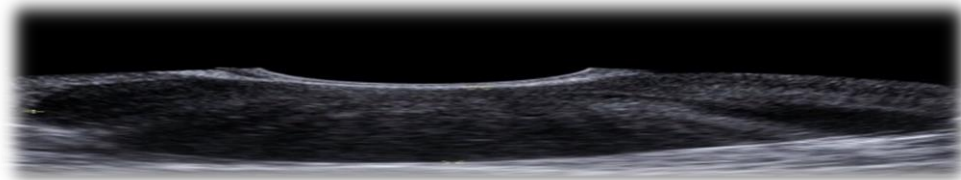
The most common benign tumor reported to have ovarian torsion is dermoid and its diagnosis is based on the clinical presentation. If ovarian torsion is suspected, then an emergency surgical intervention should be performed to prevent ovarian damaged. We report a case of unilateral ovarian torsion treated bt. Laparotomy, ovarian detorsion and cystectomy.

2. Case Report

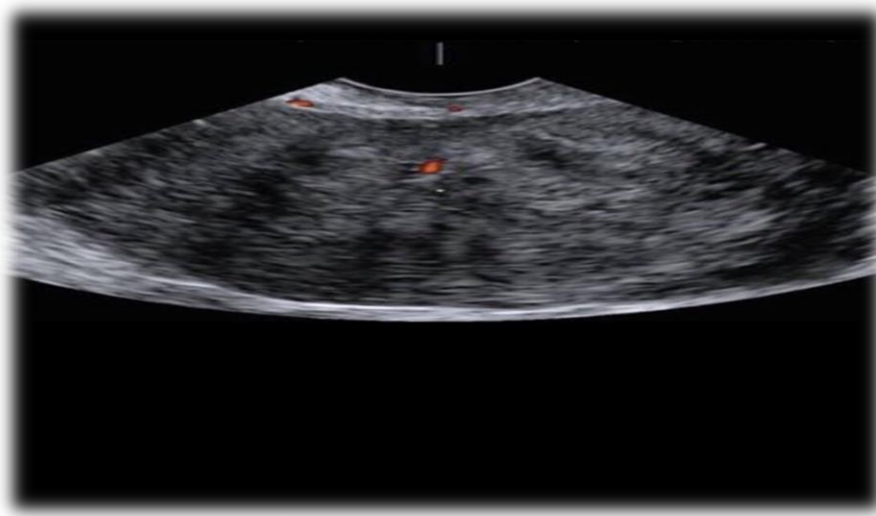
It is reported the case of 23 years old Nulliparous female Libyan, presented to our institution with history of sudden onset of sever lower abdominal pain and nausea. The pain described as constant sharp radiated to her back and associated with episode of vomiting after few hours , similar episode of pain were experienced I the previous few months and diagnosed as a case of unilateral dermoid in another hospital but case not documented .

This episodes of pain were, however shorter in duration and there were no other associated gastrointestinal or gastro urinary symptoms. Bedside demonstrating unilateral cystic mass on the Right side around 10x 9 cm with negative Doppler flow She had no previous history of any illness or allergies.

An ultrasound examination was performed in the ovarian tissue with evidence of solid components.



On the basis of these findings, ovarian torsion caused by adnexal mass was the likely diagnosis. A presumptive diagnosis of unilateral ovarian torsion was made and she was consulted on the need for an emergency Exploratory Laparotomy, decision to incision time was about 30 minutes, Intra operative findings confirmed unilateral ovarian torsion that was the same size as that found by ultrasound.



There was no ascites, Right ovary were enlarged approximately as estimated by ultra sound scan. The Right ovary had twisted on their infundibula pelvic ligaments, slightly edematous with intact capsule and locked viable, there was no evidence of hemorrhage or adhesion. The uterus, bilateral fallopian tubes and remainder intra peritoneal contents appeared to be normal. The ovaries were untwisted and unilateral cystectomy (i.e. Right) was done. There were no intra operative complication, she was managed with intravenous fluid and antibiotics. She made an unremarkable, the pain resolved completely after surgical and final pathologic diagnosis was unilateral mature ovarian teratoma (dermoid). She was discharged on the 3rd post-operative day and advised to follow up after 4th week. She recovered completely from her surgery and has gone back to her normal life.

3. Discussion

Mature cystic ovarian teratoma are benign ovarian tumor , accounting for about 95% of all ovarian teratoma , and about 10 to 20% of all ovarian tumor [6]. It can happen in all age groups however it is the most common ovarian tumor encountered in women in their 20's and 30's [7] .It is through to arise from the germ cell of the ovary and it is composed of cystic material and organized structures. All the three cell layers can be found in it, microscopically it often contains many cystic area with teeth, hair or hairs mixed with sebaceous, sticky and foul smelling material. Commonly mature cystic teratomas of the ovary are unilateral except in about 8-15% of cases were found to be bilateral [8, 9]. The most common complication is torsion; whereas rupture and suppuration is common complication. [10]

In the present case, acute sharp and constant pelvic pain was the presenting symptoms of the unilateral dermoid cyst torsion were diagnosed. The most common symptoms of ovarian torsion is

acute onset of lower abdominal pain, followed by nausea and vomiting.[11].The ovarian enlargement is one of the risk factor for the torsion , in 80 % of ovarian torsion , the ovaries measure more than 5 cm. [12]. The most common benign tumor reported to have ovarian torsion is mature ovarian teratoma (dermoid cyst). Imaging studies, including high resolution real time, two dimensional Ultra sonography and computer tomography are helpful in the differential diagnosis of dermoid cyst, but are not so useful in showing the site of torsion of the ovarian cyst, Color flow Doppler mapping may be helpful in localizing the tumor torsion. [13]. In the present case, the diagnosis was confirmed by a bedside ultrasound examination which demonstrated unilateral ovarian cyst mass, accompanied by negative Doppler flow in the ovarian tissue with the evidence of solid components.

The diagnosis of ovarian torsion depends on a detailed history, examination and imaging. Pelvic ultrasound which is the initial imaging of choice will show enlarge ovarian mass with either an absent in Doppler flow or reduce flow in the vessel due to torsion of the ovary. [14-15].

The diagnosis of torsion in this case was not challenge because of the classical history of sudden of lower abdominal pain and examination finding of tender lower abdomen with palpable mass, the diagnosis was later confirmed with ultrasound finding of unilateral adnexa mass with no flow on Doppler interrogation, Management of torsion of the ovary is surgical either through Laparoscopy or through laparotomy [16]. In this case, was prompt managed with laparotomy and cystectomy other detorsion of ovaries the reason of the above management was chosen because patient was young. Nulliparous woman and desired fertility and no sign of malignancy.

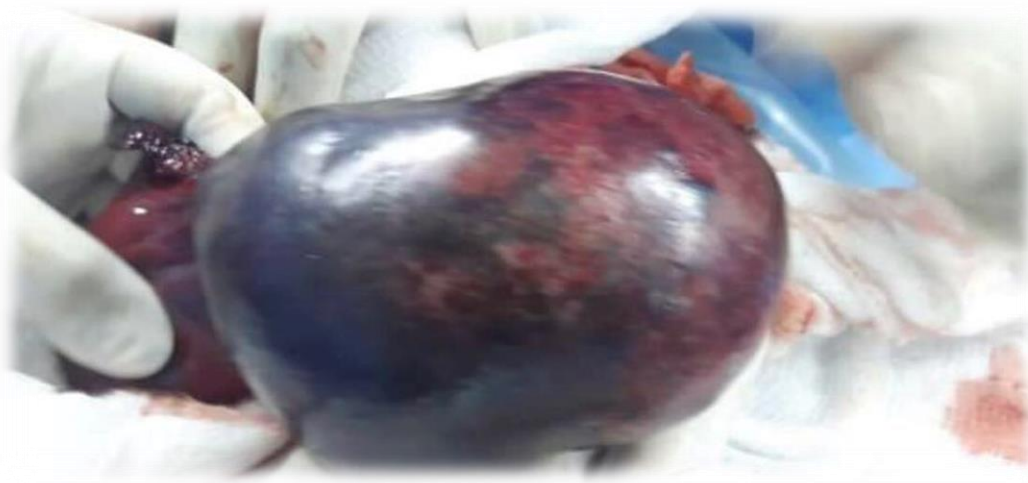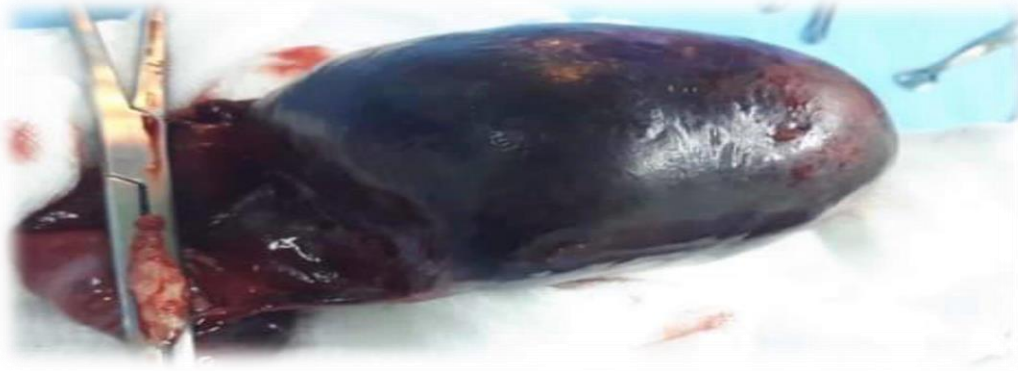The main benefit of our management was the ability to be able grossly determine the viability of the ovary after detorsion were emphasize that early surgical intervention should be considered. In case of large cyst to prevent complication such as torsion which occurred in our case.





4. Conclusions

Our case of unilateral ovarian torsion in nulliparous woman who was seen earlier in our outpatient department with unilateral ovarian mass only for her to come as an emergency and it's show the need for early surgical intervention in a nulliparous women with confirmed of big unilateral ovarian mass, so as to prevent emergencies like torsion and when these emergencies do occur prompt diagnosis and surgical intervention should be done and surgical intervention should be done to salvage the ovaries.



References

- [1] Sah, S. (2004) "Germ cell tumors of the ovary: A clinic pathological study of 121 cases, Nepal Journal of Obstetrics and Gynecology, No. 30, V4, pp 303-308
- [2] Inkdlu, S. (2015) "An usual age presentation of mature cystic teratomas : A case report, International Journal of Reproductive and contraceptives, Obstetrics and Gynecology, No. 4, V4, pp 1234-1236.
- [3] McWilliams, G. D, and Hill D. (2008) Gynecologic emergencies Surgery Clinics , North Am, No. 88, pp 265-83.
- [4] White, S J. (2005) Ovarian Torsion: 10 year perspective. Emergency Med. Australas, No.17, 231-237.
- [5] Bazot, M., and Cortez, S (1999) Imaging of dermoid cyst with foci of immature tissue, Comput Assist Tomogr, No.23, pp 703-706.
- [6] Ayan, A., and Bulkomez, O. G (2000) Mature Cystic Teratoma of the ovary case series from one institution ovaryb34 years, Eur j obstet gynecol reprot Biol, No. 88, p153.
- [7] Lakkis, W. M, and Gelfand, M. M (1985) Benign cystic teratoma of the ovary: a 6year review. Can J surg, No. 28, PP 444-446.
- [8] Pepe, F., and Panella, M. Pepe,G., Panella, P. and Pennisi, F. (1986) the presence of a unilateral mature cyst teratoma, man_ - Dermoid cysts of the ovary. Eur J. Gynaecol Oncol, No. 7, pp186-191
- [9] Outwater, E. K., Siegelman, E. S.,and Hunt, J.L (2001) Ovarian Teratomas Tumor types and Imaging Characteristics Radio Graphics, No. 21, p 47590.
- [10] Comerci, J. T., Jr Licciardi, F., Benign, P. A (1994) Mature Cystic Teratoma a Clinicopathologic Evaluation of 517 cases and review of the Literature , Obstet Gynecol, No. 84, pp 8-22.
- [11] Houry, D., and Abbott, J. T (2001) Ovarian Torsion: A fifteen year review, Ann Emerg Med, No. 38 pp 156-159.
- [12] Ci, H, and Mun-Kun, H., and Dah-Ching, D (2017) A review of ovarian torsion, Tzu Med Journal, No. 29, V 3, pp143-147.
- [13] Pascual, M. A, and Tresserra, F., and Lopez –Marin, L., and Ubeda A., Grases, P. J., Dexeus, S. (2000) Role of Color Doppler Ultrasonography in the Diagnosis of Endometrioitc Cyst J. Ultrasound Med. No. 19, pp 695-699.
- [14] Wilkinson, C., and Sanderson, A (2001) Adxenal torsion a multimodality imaging review, Clain Radiol, No. 67, pp 476-483
- [15] Lee, E. J., Kwon, H. C., Joo, H. J., Suh, J. H., Fliesche, R. A. C (1998) Diagnosis of Ovarian torsion with the color Doppler Sonography: Depiction of twisted vascular pedicle J. Ultrasound Med, No. 17, pp 83-89.
- [16] Tsafirir, Z., Hasson, J., Levin, I., Solomon, E., Lessing, J. B (2012) Adnexal torsion: Cystectomy and ovarian fixation are equally important in preventing recurrence. Eur Journal of Obstet Gynecol Reprod Biol, No. 162, pp 203-205.